KG HOSPITAL

DISCHARGE SUMMARY & DIAGNOSTIC REPORT

Coimbatore, TN | Emergency: +91 98765 12345

PATIENT PROFILE

- Name: ARULKUMARAN K (45Y/M)
- ID: KG-2024-001 | Aadhar: 1234 5678 9012
- Admission: 25-03-2024 (10:00) | Discharge: 31-03-2026 (12:00)
- Primary Surgeon: Dr. Senthil

CLINICAL FINDINGS & DIAGNOSIS

- Diagnosis: Acute Appendicitis.
- Surgical Procedure: Emergency Appendectomy (performed on 25-03-2024).
- Hospital Course: The patient underwent an uncomplicated surgical removal of the appendix. Post-operative recovery was stable with managed pain levels and no signs of infection at the incision site.

ULTRASOUND (USG) ABDOMEN SCAN REPORT

The following image represents a standard diagnostic ultrasound for this condition:

- Visual Observations: The scan shows a longitudinal cross-section of the Right Lower Quadrant (RLQ). It resembles a distended, non-compressible tubular structure with a thickened wall (approx. 7.2mm). There is minimal periappendiceal fluid, consistent with acute inflammation.
- Impression: Features are highly suggestive of Acute Appendicitis.
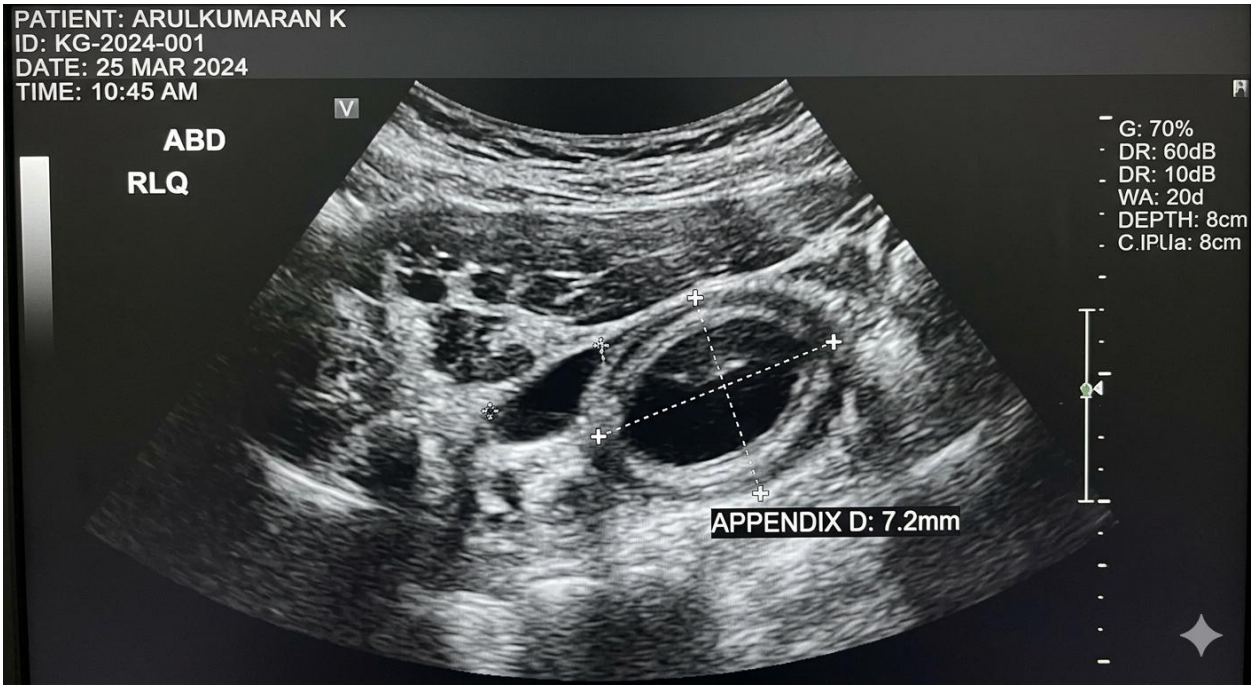
SCAN IMAGE (DIAGNOSTIC REFERENCE)